

Case notes

Name: N.P.
Gender: M F
Date of birth: 20/06/1926
Date of admission: 13/09/2013

1605

Presenting complaint

Admitted from medical clinic with palpitations, chest pain and shortness of breath. She became particularly distressed at her sister-in-law's funeral this morning.

Unwell for past few weeks with increasing shortness of breath, episodes of fast, irregular palpitations and lower leg oedema.

Recent short-stay admission to hospital one month ago with same complaints. Investigations then showed an ECG with junctional ectopics, RBBB; troponin normal. Sent home for planned review in medical clinic. Since that time BP had been high (SBP 170–190mmHg) and GP (Dr A) had increased her lercanidipine from 10mg mane, 5mg nocte to 10mg bd.

She has a background history of cardiovascular disorders as follow:

- Hypertension has been treated since 1966. It has been difficult to control and she sees a specialist for this, Dr B.
- Episodes of palpitations have been present since the end of 2008 and in July 2009 her ECG showed first degree AV block and RBBB; Holter monitoring showed multiple supraventricular ectopics, moderately frequent VPBs and short episodes of SVT.
- Episodes of dizziness were a problem in 2008–09 but not since. She has never fainted.
- Hypercholesterolaemia was diagnosed in 2009 but her recent lipids show high HDL 2.86mmol/L and LDL 3.3mmol/L.

No prolonged episodes of chest pain; no known AMIs.

Leg swelling has increased over the past few weeks.

There have not been any past stroke, TIA or focal neurological symptoms.

Other active problems

- Hypothyroidism – partial thyroidectomy 1991; on thyroxine since 1993. TSH 0.41mIU/L (0.35-5.5) Mar2013.
- Osteoarthritis – back, hips, knees since 2009. Lumbar spinal stenosis (L4-5) noted on MRI 2011. Panadol osteo bd helps to control pain. She gets lower back and knee pains mainly.
- Osteoporosis – fracture of ankle March 2005 and osteoporosis diagnosed; she was on Fosamax for some years. This was complicated by dental problems and drug ceased 2010. Vitamin D deficiency noted 2009 and on Ostelin Vit D 1000U/d since.
- Gastroesophageal reflux disease – first detected in 2007 on endoscopy, and on treatment with Nexium since.
- Recurrent episodes of pancreatitis in 2012 – recurrent abdominal pain.

- Probable renal carcinoma left kidney noted on CT as a 23mm mass; also L kidney mid-pole calculus. Annual CT scans and FU by urologist Dr S.
- Poor dentition.

Past history

2005 Dry eye syndrome

Aug 2008 L inguinal hernia repair

Aug 2009 L shoulder injury; Supraspinatus tendon tear

Dec 2011 Hyponatraemia (126mmol/L) 2° to hydrochlorothiazide

Social history

Born in Serbia of Jewish descent. Sponsored by brother-in-law and sister-in-law (died last week) to come to Australia in 1948. Worked in family business until retirement 15 years ago. Lives with husband who has heart disease (IHD, AF and heart failure) who has been in failing health for past year. They are well supported by two daughters and families who live nearby.

Drug allergies/ADRs

Thiazide – hyponatraemia
 Frusemide – dizzy; ‘too strong’ for her
 Fosamax – problems with dentition

Current therapy

Metoprolol 12.5mg bd
 Candesartan 16mg mane
 Lercanidipine 10mg bd
 Esomeprazole 20mg nocte
 Thyroxine 100microg twice a week (M, Th); 50microg other days
 Ostelin Vit D 1000U mane
 Aspirin (Astrix) 100mg mane

Physical examination

- Elderly woman looking sad but not unduly distressed; iv in situ L forearm, ECG monitored and on O2 via nasal prongs.
- Short of breath on minimal effort.
- BP sitting 162/89mmHg (machine reading); ECG trace showing RBBB, atrial fibrillation with rapid VR 150/min.
- JVP 2–3cm; HS irregular, no murmurs.
- Chest – bibasal crackles.
- Pitting oedema to mid calves.
- Abdomen – no masses or ascites.
- Osteoarthritis of knees with restricted range of movement both sides.
- Small lymph node apex R posterior triangle neck. No other nodes noted.

Assessment

AF with chest pain ? coronary ischaemia and CCF.

Plan

1. Admit to Cardiology ward.
2. Troponins/CXR/U&E/Thyroid function.
3. Stop lercanidipine.
4. Increase metoprolol to 25mg bd, slowly titrating it (needs monitoring of HR).
5. Worthwhile to get echocardiogram to document LV function once HR improves.
6. Need to consider warfarin if no contraindications.

RA JMO #1123

13.09.13 1845 PM Nursing

Pt arrived on ward @ 1630. Pt A & O. Afebrile. Nil c/o pain. Obs BP 171/83, HR 78 AF. Peripheries warm/perfused. NCOOB. SpO2 100% at RA.

Bloods sent to pathology as ordered by Cardiology HMO on ph #4569; first troponin normal; HMO informed regarding R/V. Metoprolol 25mg given as charted. Skin integ D & I. Pt monitored. Independent of ADLs PVIT. Tolerating food/fluids well. AH CNS.

13.09.13 1920 JMO

Review of recently admitted patient. 87yo F in AF with RVR at clinic today. Patient reports episodes of rapid palpitations going back into her middle age, however most treatment has been for hypertension which she has had for many decades.

Had 4-5-episodes of palpitations in 2012. Reports more frequent episodes this year. Since Aug they have been almost constant with associated SOB & chest discomfort.

No recent change in thyroxine dose.

Previously well – no infections.

Recent social stressors – funeral of close family member.

O/E

BP 171/83, HR 78 RR 20 SpO2 100% RA

Heart – HS irregular, Lungs – clear

Pitting oedema ankles

ECG: RBBB (old) and AF with RVR (on admit to ward)

Plan

1. Chase pending bloods
2. Liaise with Reg re anticoagulation.

RA #1123

14.09.13 0320 Nursing ND

ID bands ✓, safety checks ✓ GCS 15 Pt c ongoing chest discomfort & reports 2-3/10 dull ache L side. ECG completed. Pt pain self-resolved. Paged Dr M & had phone order for anginine. Pt reports pain free by time organised. R/V pt at 0400 re clexane pt still pain free and aware to inform nurse if any CP. Dr M charted prn anginine. Neurovasc: P, W & D. CVS: pt monitored SR

with occasional atrial ectopics with compensatory pauses. ECG printed. Afebrile. RESP: SpO2 rest 100% RA/ RR 18 No SOB or incr WOB. RENAL: Pt I voiding no witnessed voiding so far. Pt given oral Magmin to replace magnesium. All other pathology as chart. Vital signs as charted BP 145/76, come down from previous. HR 86. Nil further issues at TOR. NIC aware pt path results. Nil further orders to be R/V in AM. LB RN1

Indwelling Vascular Advice
Type: 22G
Site: R hand
Main reason for insertion: Ongoing CP
Insertion date: 14.09.13
Inserted by: AB

S/V by EL

14.09.13 0730 Nursing ND

Additional: 0500 Pt vital signs checked 174/80 HR 74 irregular. Pt c/o 4/10 chest heaviness on L side. Dr paged. ECG taken & printed. Pt given 2 × ½ tablet anginine from phone order chart as per NIC request until Dr A arrived on ward. Anginine prn order incomplete & Dr A rewrote. Sc/iv morphine charted. No further troponin or bloods to be taken as per Dr A requests. Pt to have sc morph. No IVD. Pt given 2.5mg sc morphine to little effect. Pt initially placed on face mask then changed to NP and PO2 kept >95% at all times as per Dr A request. IVB inserted by NIC & further 2.5mg morphine given iv. CP remained. Dr A paged and came to R/V pt; further tablet anginine given. Metoprolol 12.5mg given early at 0200 as per Dr A request. Total 3 × anginine tablets, 5mg morphine & 12.5mg metoprolol given. Pt reluctant to report CP must be re-educated & encouraged to report. Pt handed over to morning staff. All regular observations as per charts. No further issues at NR. To be R/V by Cardiol this AM.

14.09.13 1130 Cardiol WR

#1 AF – now in SR

Years of palps off & on becoming more frequent; when has palps gets chest pressure L sided. Feels better now.

Plan

1. Cease metop. & commence amiodarone for 400 mg tds 1/52 then to bd 1/52 then to 200mg daily.
2. Rivaroxaban 15mg/d for stroke prophylaxis.

RA #1123

14.09.13 1300 AM Nursing

Pt A & O Afebrile. Pt c/o chest discomfort early in the shift. Refused anginine/morphine. Pt had 3 episodes of vomit & bradycardia HR 34 at one stage BP 155/60 HR 67 sinus arrhythmia c AVP & A flutter. Rhythm/rate varied during episodes. Frequent ECGs done. Cardiology HMO kept informed regarding incidents. Candesartan & Maxalon given for nausea with good effect. SOBOE SpO2 95% on RA. R arm iv bung inserted. Trop -ve, K 4.0, Mg 0.82 replaced as charted. Skin integ D & I. Pt ambulates to toilet. Tolerating food/fluids well. BNO. Visited by family. Nil other issues. CA CNS

14.09.13 1500 HMO

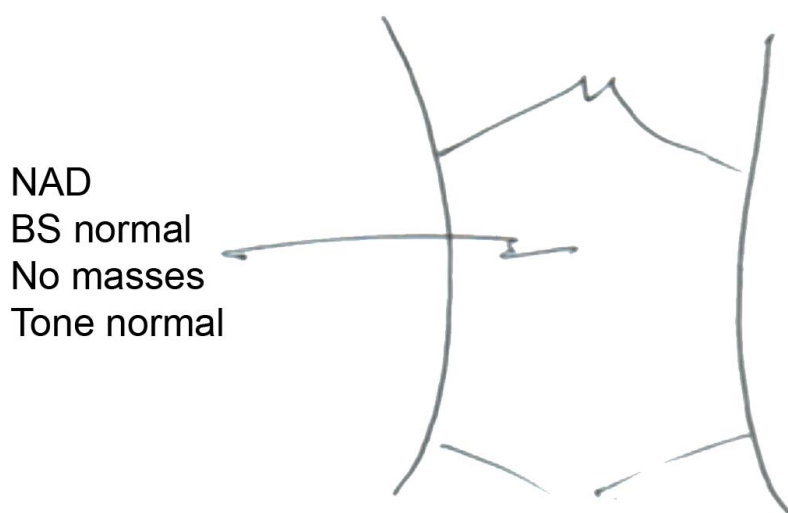
R/V of pt following 2nd episode of vomiting at 1330. 1st episode this am around 0930-1000. Vomiting associated with bradycardia (down to 40) also tachycardia (up to 175). As per Dr M likely 2° to emesis; not concerned.

Vomiting a/w nausea but no dizziness, reflux, waterbrash, vertigo, abdo pain, diarrhoea or infective Sx.

PMHc includes GORD, pancreatitis (2011) however pt denies abdo pain.

Pt feels vomiting may be 2° to morphine which she received twice this AM (but before 7AM).

O/E Obs stable. Afeb.



BS present

Tone normal

Bloods WCC normal

Plan

1. Retrospective LFTs & lipase.
2. Monitor for further vomiting.
3. If requires morphine for analgesia, consider giving emetic simultaneously.

AB #4569

15.09.13 Cardiology WR

#1 AF

Back in SR. No major events O/N. Predom SR.

Pt well keen for home.

On ~~warfarin~~ rivaroxaban- explained risk bleeding.

For:

1. r/v c Cardiologist
2. Cease aspirin
3. D/C today

RA #1123